10.47519/risi.v1i00.2

Revista Ibero-Americana de Saúde Integrativa
Ibero-American Journal of Integrative Health

ACTINIC CHEILITIS: IMPORTANCE OF PREVENTION AND EARLY IDENTIFYING CLINICAL SIGNS

QUEILITE ACTÍNICA: IMPORTÂNCIA DA PREVENÇÃO E DA IDENTIFICAÇÃO PRECOCE DOS SINAIS CLÍNICOS

QUEILITIS ACTÍNICA: IMPORTANCIA DE LA PREVENCIÓN Y DE LA IDENTIFICACIÓN PRECOZ DE LOS SIGNOS CLÍNICOS

Henrique FIGUEROA VARALTA[1]
henrique@cemodonto.com.br
Jéssica dos Santos BERNINI [2]
jessicabernini@hotmail.com
Kevin Luiz Lopes DELPHINO [3]
kevinlopesdelphino@gmail.com
Gérson Aparecido FORATORI-JÚNIOR [4]
gersonforatori.usp@gmail.com
Denise Tostes OLIVEIRA [5]
denisetostes@fob.usp.br
Agnes ASSAO [6]
agnes.assao@uenp.edu.br

[1] Bachelor's Degree in Dentistry from the Integrated Colleges of Ourinhos University Center.

[2] Bachelor's Degree in Dentistry from the Integrated Colleges of Ourinhos University Center.

[3] Bachelor's Degree in Dentistry from the State University of Northern Paraná. Master's student in the Graduate Program in Cellular and Molecular Biology and Pathogenic Bioagents at the Ribeirão Preto Medical School - University of São Paulo (FMRP/USP).

[4] Doctoral degree in Applied Dental Sciences from the Bauru School of Dentistry at the University of São Paulo (FOB-USP).

[5] Doctoral degree in Dentistry (Oral Pathology) from the School of Dentistry at the University of São Paulo (FOUSP).

[6] Doctoral degree in Applied Dental Sciences from the Bauru School of Dentistry at the University of São Paulo (FOB-USP).

How to reference this article:

FIGUEROA VARALTA, H.; DELPHINO, K.; BERNINI, J. dos S.; FORATORI-JÚNIOR, G. A.; OLIVEIRA, D. T.; ASSAO, A. Actinic cheilitis: importance of prevention and ear-ly identifying clinical signs. **Revista Ibero-Americana de Saúde Integrativa (RISI)**, Bauru, v. 1, n. 00, e024007, 2024. e-ISSN: 2966-4543. DOI: 10.47519/risi.v1i00.2

Submitted: 06/03/2024
Revisions required: 15/04/2024
Approved: 10/12/2024
Published: 30/12/2024

ABSTRACT: Actinic cheilitis is a potentially malignant oral disorder that primarily affects the lower lip due to chronic and excessive exposure to ultraviolet radiation. A 61-year-old male patient presented to the university clinic with non-healing ulcers on the lower lip. On extraoral physical examination, areas of scaling, ulceration, and whitish discoloration with desquamation were observed on the lower lip, suggesting actinic cheilitis. An incisional biopsy was performed, and histopathological analysis revealed the presence of buccal mucosa composed of parakeratinized stratified squamous epithelium with areas of basophilic transformation of collagen, confirming the diagnosis of actinic cheilitis. The patient was advised to protect against sun exposure and is under follow-up with no signs of recurrence. This clinical case highlights the importance of early diagnosis of actinic cheilitis, as well as educating the population about this pathology, given its potential progression to squamous cell carcinoma of the lip.

KEYWORDS: Actinic cheilitis. Squamous cell carcinoma. Lip.

RESUMO: *A queilite actínica é uma desordem oral potencialmente maligna, que afeta principalmente o lábio inferior, devido a exposição crônica e excessiva à radiação ultravioleta. Um paciente do sexo masculino, 61 anos, se apresentou à clínica universitária com úlceras no lábio inferior que não cicatrizavam. Ao exame físico extra-bucal, observou-se a presença de áreas de descamação no lábio inferior, ulceradas e esbranquiçadas, com descamação, sugerindo a queilite actínica. Procedeu-se à biopsia incisional e, de acordo com a análise histopatológica, constatou-se a presença de uma mucosa bucal constituída por epitélio estratificado pavimentoso paraqueratinizado, com áreas de transformação basofílica do colágeno, confirmando o diagnóstico de queilite actínica. O paciente foi orientado acerca da proteção contra a exposição solar e está em acompanhamento, sem sinais de recidiva. Este caso clínico reforça a importância do diagnóstico precoce da queilite actínica, assim como da orientação à população sobre esta patologia, visto que antecede a progressão para o carcinoma espinocelular de lábio.*

PALAVRAS-CHAVE: *Queilite Actínica. Carcinoma espinocelular. Lábio.*

RESUMEN: *La queilitis actínica es un trastorno oral potencialmente maligno que afecta principalmente al labio inferior debido a la exposición crónica y excesiva a la radiación ultravioleta. Un paciente varón de 61 años acudió a la clínica universitaria con úlceras que no cicatrizaban en el labio inferior. En la exploración física extraoral se observaron zonas de descamación ulceradas y blanquecinas en el labio inferior, sugestivas de queilitis actínica. Se realizó una biopsia incisional y el análisis histopatológico reveló la presencia de una mucosa oral formada por epitelio pavimentoso estratificado paraqueratinizado, con áreas de transformación basófila del colágeno, lo que confirmó el diagnóstico de queilitis actínica. Se aconsejó al paciente que se protegiera de la exposición solar y está en seguimiento, sin signos de recidiva. Este caso clínico refuerza la importancia del diagnóstico precoz de la queilitis actínica, así como la educación de la población sobre esta patología, ya que precede a la progresión a carcinoma escamoso de labio.*

PALABRAS CLAVE: *Queilitis Actínica. Carcinoma de células escamosas. Labio.*

Article submitted to the similarity system

iThenticate

Chief Editor: Prof. Dr. Kaique Cesar de Paula Silva
Executive Editor and Scientific Publishing: Prof. Dr. José Anderson Santos Cruz

INTRODUCTION

According to the World Health Organization (WHO) classification of 2017, Potentially Malignant Oral Disorders (PMODs) are defined as clinical presentations that carry a risk of developing cancer in the oral cavity. Actinic Cheilitis (AC), in turn, is a clinical condition with this potential, primarily affecting the lower lip region (Reibel, 2017; Muse, Crane, 2023). This lesion is associated with chronic and progressive exposure to ultraviolet (UV) light, predominantly affecting fair-skinned males over the age of 40 (Muse, Crane, 2023; Cremonesi *et al.*, 2017; Mello *et al.*, 2019; Moreira *et al.*, 2021).

In its early clinical stages, patients commonly present with dryness, atrophy, erythema, and fissures in the vermilion border of the lip (Mello *et al.*, 2019; Moreira *et al.*, 2021). As the condition progresses, areas of scaling, roughness, and induration may develop in regions initially presenting dryness, with the boundary between the lip and the adjacent skin becoming indistinct. Eventually, chronic ulceration may occur, particularly in patients who smoke (Moreira *et al.*, 2021; Ribeiro *et al.*, 2014; Martins-Filho *et al.*, 2011).

The incidence of AC is higher in regions near the Equator. In Brazil, it is particularly noteworthy due to the country's tropical climate and the significant proportion of its economy reliant on rural activities, where workers are frequently exposed to prolonged sun exposure (Mello *et al.*, 2019; Moreira *et al.*, 2021; Martins-Filho *et al.*, 2011). It is estimated that approximately 95% of lip squamous cell carcinomas are preceded by AC (Mello *et al.*, 2019).

The main etiological factor for Actinic Cheilitis is chronic and progressive UV light exposure (Araújo *et al.*, 2012; Martins-Filho *et al.*, 2011; Ribeiro *et al.*, 2014). However, other factors may also contribute to its malignant transformation, such as alcohol consumption, smoking, socioeconomic factors, and genetic predisposition (Araújo *et al.*, 2012; Cremonesi *et al.*, 2017; Martins-Filho *et al.*, 2011).

Considering the high malignancy potential of Actinic Cheilitis, approximately 16% of cases (Lucena *et al.*, 2012; Martins-Filho *et al.*, 2011; Moreira *et al.*, 2021), this study aims to report a clinical case of Actinic Cheilitis to alert dentists and the general population to the importance of early diagnosis and management of this condition. Early intervention significantly reduces the impact of more invasive treatments on the patient.

CASE REPORT

A 59-year-old male, leucodermic and driver, was referred to the university clinic with a chief complaint of a non-healing lip sore. During the anamnesis, the patient reported a six-month evolution of the lesion and stated that he worked outdoors under sun exposure without any protective measures. The patient resides and works in a rural area in the western region of São Paulo state.

10.47519/risi.v1i00.2

On physical examination, ulcerated areas were identified on the lower left labial mucosa, located at the transition zone between the lip mucosa and the skin. The lesions appeared ulcerated, interspersed with whitish and dry areas, with undefined margins and indurated edges (Figure 1).

The differential diagnoses included Actinic Cheilitis or lip squamous cell carcinoma based on the clinical features observed. An incisional biopsy was performed (Figure 2), and the specimen was sent for histopathological analysis.

Microscopically, the presence of oral mucosa composed of orthokeratinized and hyperplastic stratified squamous epithelium and fibrous connective tissue with moderate subepithelial mononuclear inflammatory infiltrate was observed. No epithelial dysplasia was detected. Areas of basophilic collagen transformation were also noted (Figure 3), confirming the diagnosis of Actinic Cheilitis.

The patient was advised on the importance of sun protection, including the use of lip sunscreen and hats. At the 14-day postoperative follow-up, proper wound healing, improvement in the lip's appearance, and the absence of lesion recurrence were observed (Figure 4).

Figure 1 - Initial clinical appearance.



Source: Dental Clinic of the University Center of Faculdades Integradas de Ourinhos.

Figure 2 - Selected area for incisional biopsy of the lesion.

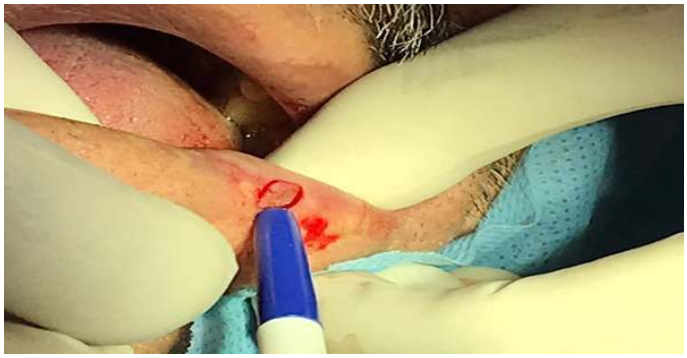

Source: Dental Clinic of the University Center of Faculdades Integradas de Ourinhos.

10.47519/risi.v1i00.2

Figure 3 - Oral mucosa composed of stratified squamous parakeratinized and hyperplastic epithelium. Subjacent to this, the presence of a mononuclear inflammatory infiltrate and areas of basophilic collagen degeneration are observed (H&E, 10x).

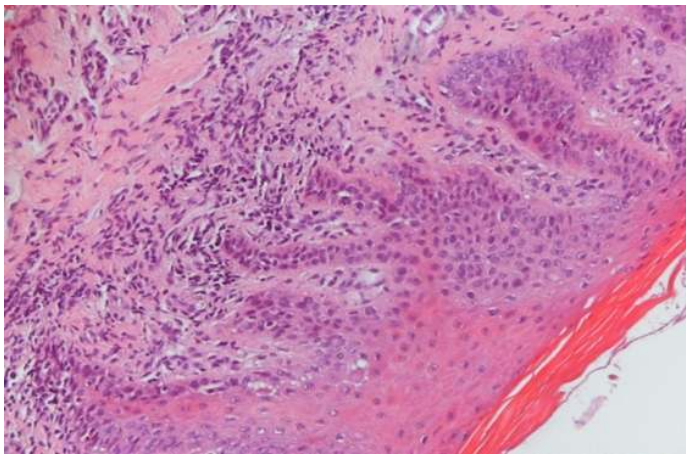

Source: Department of Pathology/FOB-USP.

Figure 4 - Postoperative clinical appearance at 14 days.



Source: Dental Clinic of the University Center of Faculdades Integradas de Ourinhos.

DISCUSSION

Although actinic cheilitis is a relatively common potentially malignant oral disorder in tropical countries, such as Brazil, the data related to the prevalence of this lesion are highly variable across the country (Moreira *et al.*, 2021), which can be attributed to the location where the survey was conducted, the degree of sun exposure, and occupation. The observed prevalences range from 16.7% to 34.6% among rural workers exposed to the sun (Martins-Filho *et al.*, 2011; Moreira *et al.*, 2021).

In addition to sun exposure, some studies observe an association between smoking

10.47519/risi.v1i00.2

and the development of actinic cheilitis (Cintra *et al.*, 2013; Lucena *et al.*, 2012; Martins-Filho *et al.*, 2011; Moreira *et al.*, 2021). According to Martins-Filho, da Silva, and Piva (2011) and Cremonesi *et al.* (2017), continuous exposure to high temperatures and harmful tobacco products increases the chances of changes in the labial epithelium, and when combined with exposure to UV radiation, these factors undoubtedly lead to the malignant progression of the lesion.

Clinically, it is essential to critically analyze the aspects of actinic cheilitis, considering that a detailed physical examination and anamnesis can guide the dentist to the correct diagnosis and treatment, allowing early intervention in the lesion. Initially, acute lesions of actinic cheilitis appear as edematous areas with moderate redness and vesicles that quickly rupture, forming ulcers (Carvalho *et al.*, 2019). Chronic forms, resulting from cumulative exposure to UV radiation, initially present as solitary, whitish lesions that can progress to multifocal erosive or ulcerated areas, with the frequent presence of fissures and atrophy (Cremonesi *et al.*, 2017; Ribeiro *et al.*, 2014).

Other clinical signs that facilitate the identification of actinic cheilitis include dryness, scaling, loss of delineation between the vermilion of the lip and skin, edema, and crust formation (Moreira *et al.*, 2021). The presence of crusts has been significantly associated with actinic cheilitis with severe epithelial dysplasia and carcinoma in situ and should necessarily be biopsied (Mello *et al.*, 2019).

Symptoms are rare in actinic cheilitis, but some patients report a burning and stinging sensation, which may contribute to them seeking clinical care (Ribeiro *et al.*, 2014).

Biopsy is the most recommended complementary exam for the correct diagnosis of actinic cheilitis (Araújo *et al.*, 2012; Carvalho *et al.*, 2019; Cremonesi *et al.*, 2017), with the degree of epithelial dysplasia present in the lesion being the determining factor for the choice of therapeutic approach. In cases of epithelial dysplasia, treatments may vary from surgical therapies for mild, moderate, or severe dysplasias (surgical excision, cryosurgery, laser surgery) to non-surgical therapies for actinic cheilitis without epithelial dysplasia (guidance on sun exposure and follow-up, topical chemotherapy with 5-fluorouracil, imiquimod, photodynamic therapy, and dermabrasion) (Araújo *et al.*, 2012).

FINAL CONSIDERATIONS

The reported clinical case reinforces the importance of early diagnosis of potentially malignant oral disorders, such as actinic cheilitis, particularly in Brazil, where its incidence is high. Guidance on the prevention and monitoring of these lesions is essential, highlighting the fundamental role of the dentist in diagnosing and managing these conditions and preventing potential progression to oral cancer.

10.47519/risi.v1i00.2

REFERENCES

ARAÚJO C.P.; VIDAL, M. T. A; GURGEL, C. A. S; RAMOS, E. A. G.; JUNIOR, A. A. B.; RAMALHO, L. M. P.; SANTOS, J. N. Queilite actínica: um estudo de 35 casos com destaque para os aspectos morfológicos. **RPG Rev. Pós Grad.**, Faculdade de Odontologia da Universidade Federal da Bahia (FOUFBA), Salvador, v. 19, n. 1, p. 21-7, 2012.

CARVALHO, M. V.; DE MORAES, S. L. D.; LEMOS, C. A. A.; SANTIAGO JÚNIOR, J. F.; VASCONCELOS, B. C. D. E.; PELLIZZER, E. P. Surgical versus non-surgical treatment of actinic cheilitis: A systematic review and meta-analysis. **Oral Dis.**, v. 25, n. 4, p. 972-981, 2019. DOI:10.1111/odi.12916.

CINTRA JS, TORRES SCM, SILVA MBF, JUNIOR LRCM, FILHO JPS, JUNQUEIRA JLC. Queilite Actínica: Estudo epidemiológico entre trabalhadores rurais do município. **Rev Assoc. paulista Cir. Dent.**; v. 67, n. 2, p. 118-21, 2013. Available at: http://revodonto.bvsalud.org/scielo.php?pid=S000427620130002000006&script=sci_abstract&tlng=pt. Accessed in: 17 mar. 2021.

CREMONESI AL, QUISPE RA, GARCIA ASM, SANTOS, PSS. Queilite actínica: um estudo retrospectivo das características clinicas e histopatológicas. **Arq Med Hosp Fac Cienc Med Santa Casa São Paulo**. v. 62, n. 1, p. 7-11, 2017.

LUCENA, E. E. S; COSTA, D. C.; DA SILVEIRA, E. J.; LIMA, K. C. Prevalence and factors associated to actinic cheilitis in beach workers. **Oral Dis.**, v. 18, n. 6, p. 575-579, 2012. DOI: 10.1111/j.1601-0825.2012.01910.x.

MARTINS-FILHO P. R.; SILVA, L. C.; PIVA, M. R. The prevalence of actinic cheilitis in farmers in a semi-arid northeastern region of Brazil. **Int J Dermatol.** v. 50, n. 9, p. 1109-1114, 2011. DOI: 10.1111/j.1365-4632.2010.04802.x.

MELLO, F. W.; MELO, G.; MODOLO, F.; RIVERO, E. R. Actinic cheilitis and lip squamous cell carcinoma: Literature review and new data from Brazil. **J Clin Exp Dent.** v. 11, n. 1, p. e62-e69, 2019. DOI:10.4317/jced.55133.

MOREIRA P, ASSAF AV, CORTELLAZZI KL, TAKAHAMA JUNIOR A, AZEVEDO RS. Social and behavioural associated factors of actinic cheilitis in rural workers. **Oral Dis.** v. 27, n. 4, p. 911-918, 2021. DOI:10.1111/odi.13610.

MUSE, M. E.; CRANE, J. S. Actinic Cheilitis. In: **STATPEARLS.** StatPearls Publishing, 2023.

RIEBEL, J.; TILAKARATNE, W.; GALE, N.; WESTRA, W.; HILLE, J.; WILLIAMS, M. Oral potentially malignant disorders & oral epithelial dysplasia. In: EL-NAGGAR, A. K.; CHAN, J. K. C.; GRANDIS, J. R.; TAKATA, T.; SLOOTWEG, P. J. (ed.). **WHO classification of head and neck tumours.** 4. ed. Lyon: International Agency for Research on Cancer, 2017. p. 112–115.

DE OLIVEIRA RIBEIRO, A.; DA SILVA, L. C.; MARTINS-FILHO, P. R. Prevalence of and risk factors for actinic cheilitis in Brazilian fishermen and women. **International Journal of Dermatology,** v. 53, n. 11, p. 1370–1376, 2014. DOI:10.1111/ijd.12526

10.47519/risi.v1i00.2

CRediT Author Statement

Acknowledgements: Not applicable..

Funding: Not applicable.

Conflicts of interest: No conflicts of interest to declare.

Ethical approval: Yes.

Availability of data and material: Yes.

Author contributions: The authors contributed to the conception, writing, revision, editing, and supervision of the manuscript. Varalta contributed to the manuscript revision; Bernini contributed to the writing and revision; Lopes-Delphino contributed to the revision, editing, and standardization; Foratori-Junior contributed to the conception; Oliveira contributed to the data curation (pathological analysis); and Assao conceived and supervised the manuscript.

Processing and editing: Editora Ibero-Americana de Educação.

Proofreading, formatting, standardization and translation.